

## Osteoarthritis associated with osteopetrosis treated by resurfacing arthroplasty

### Report of a case

D.S. Feldman, W.L. Jaffe, L. Schulman (New York, USA)

Hospital for Joint Diseases, Orthopaedic Institute, Department of Orthopaedic Surgery, 301 East 17th Street, New York, N.Y. 10003, USA.

#### SUMMARY

Early-onset osteoarthritis of the hip associated with osteopetrosis has been described in the literature. The surgical management of these patients has been difficult and fraught with complications.

Osteopetrosis (marble bone disease) was first described by Heinrich Albers-Schonberg in 1904 in a patient presenting with generalized osteos-

clerosis and multiple fractures [Alexander (1)]. Since then the genetic, histological and clinical features have been described.

We present a case in which the existence of early osteoarthritis in association with osteopetrosis led to the insertion of a resurfacing arthroplasty.

#### CASE REPORT

Osteopetrosis in a patient aged 41 years had first been diagnosed in childhood. She had had multiple fractures and had a mild anaemia. Two years prior to her admission, she had sustained a right subtrochanteric fracture resulting from minimal trauma which had been treated by open reduction and internal fixation with a compression screw and side plate (*fig. 1*). A non-union which followed was treated one year later by a bone allograft and an anterior dynamic compression plate.

After temporary relief, she developed pain in the right groin and thigh six months later with painful limitation of movement. Radiographs showed union of the subtrochanteric

fracture and an osteoarthritis characterized by marked narrowing of the joint space and osteophyte formation (*fig. 2*). Worsening of her symptoms, with a Harris hip score of 48, led to the performance of a resurfacing hip arthroplasty (*fig. 3*).

The operation confirmed the disappearance of the articular cartilage from the femoral head and the acetabulum. The bone was very hard and brittle and of ceramic-like consistency. An attempt to fix the cup with screws was complicated by a fracture propagated between the two screw holes in the acetabular roof. The acetabular cup was therefore cemented.

Eight months after operation, the hip was painless and stable. The Harris score was 91.

Reprints : D.S. FELDMAN, address as above.

The French and English title of this paper is indexed in the main international data banks under the head « Revue de Chirurgie Orthopédique » (*Rev Chir Orthop*, 1991, 77, 503-505).

Meary Code Number : 1123.0

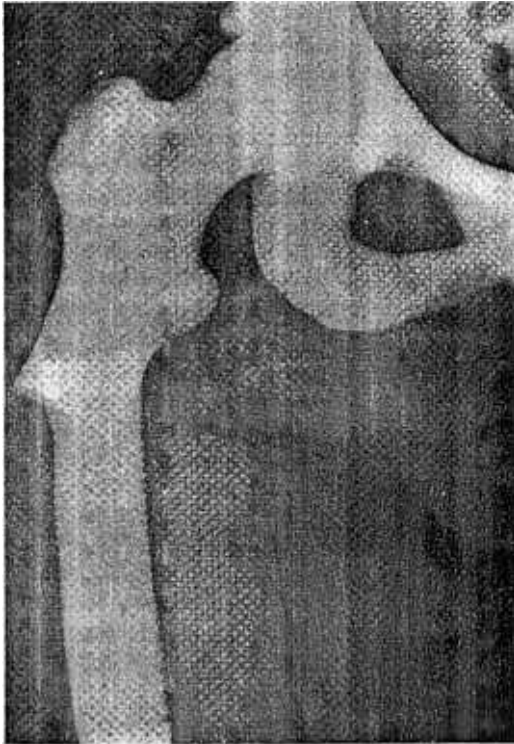

FIG. 1. — Subtrochanteric fracture of the right femur.

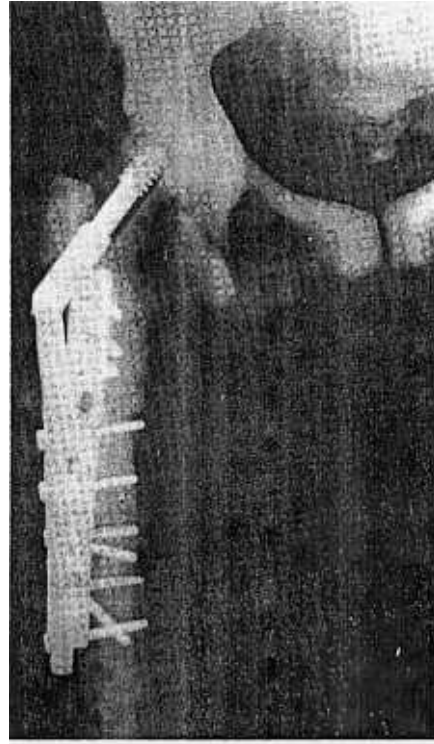


FIG. 2. — Radiograph two years after the fracture showing osteoarthritis of the hip.

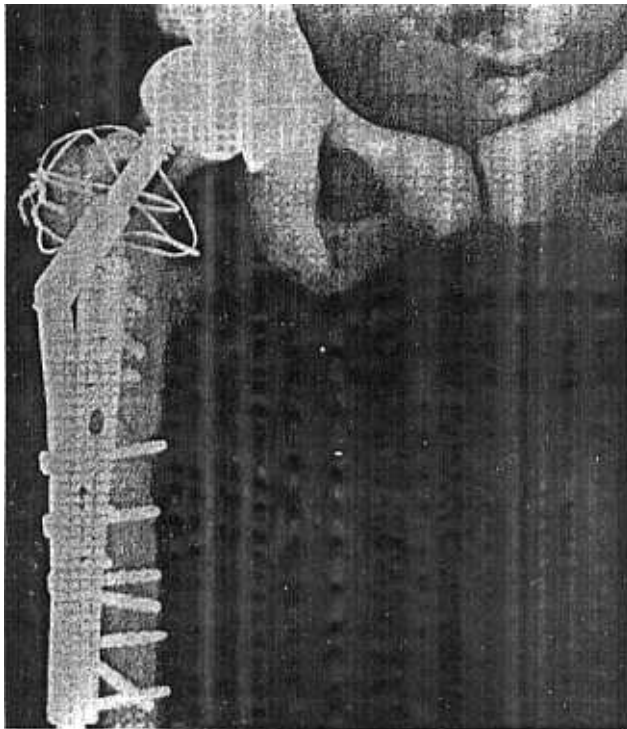


FIG. 3. — Radiograph after insertion of a resurfacing arthroplasty.

### DISCUSSION

Genetically, osteopetrosis has two forms. An autosomal recessive type is almost always fatal in the first decade of life.

An autosomal dominant type takes on a variable and more benign clinical course [Bollerslev and Andersen (3)]. The disease is due to a deficiency in osteoclasts causing a defect in bone remodelling.

Radiologically, there is a uniform and symmetrical increase in bone density with obliteration of the medullary canal by cortical bone. The classical appearance of a «bone within a bone» is due to the fact that the process can remit for a period of time and then recommence. Ehrlenmeyer flask deformity of long bones, transverse and longitudinal striations and thickening of the base of the skull are all common in osteopetrosis [Greenfield (8)].

Histologically, the disease is characterized by failure of osteoclastic resorption of both calcified cartilage and bone and failure to progress to osteonal bone. An abundance of immature bone results whose mechanical properties are inferior to those of mature lamellar bone.

The autosomal dominant type is often asymptomatic but can also be expressed by multiple fractures with

minimal trauma, anaemia, early osteoarthritis, coxa vara [King (11) and osteomyelitis of the maxilla or mandible due to poor dentition [Bogumill and Schwamm (2), Robichon *et al.* (13)]. Early osteoarthritis associated with osteopetrosis has been described by Cameron and Dewar (5), Casden *et al.* (6), and Janecki and Nelson (10). The etiological factors seem to be microfractures of the brittle subchondral bone, altered circulation in the femoral head and mechanical crushing of the cartilage between the very hard subchondral bone of the femoral head and acetabulum.

Surgical treatment for this particular type of osteoarthritis is technically difficult [Breck *et al.* (4)]. Cameron and Dewar (5) reported a case of total hip arthroplasty in which the stem of the femoral component had to be shortened because of inability to insert the stem in the medullary canal. Janecki and Nelson (10) described a case in which the lesser trochanter fractured in attempting to create a medullary canal for a stem.

Our case also demonstrates the technical difficulties related to the quality of the bone. The insertion of a screw in the acetabulum was complicated by a fracture which required cementing of the cup.

In spite of long-term failures of resurfacing arthroplasty whose rates range from 10 per cent after five years to 60 per cent after eight years [Ritter and Gioe (12), Howie *et al.* (9)] it seemed to us that this method constituted an interesting alternative in cases of osteopetrosis to limit the risk of severe complications related to the insertion of a conventional femoral stem.

#### Reference

1. ALEXANDER WG : Report of a case of so called « marble bones » with review of the literature and translation of an article. *Am J Roentgenol*, 1923, 10, 280.
2. BOGUMILL GP, SCHWAMM HA : Orthopaedic Pathology. Philadelphia. *W.B. Saunders Co*, Philadelphia, 1984, 63.
3. BOLLERSLEV J, ANDERSEN PE : Fracture patterns in two types of autosomal-dominant osteopetrosis. *Acta Orthop Scand*, 1989, 60, 110.
4. BRECK LW, CORNELL RC, EMMETT JE : Intramedullary fixation of fractures of the femur in a case of osteopetrosis. *J Bone Joint Surg (Am)*, 1975, 39, 1389.
5. CAMERON HV, DEWAR FP : Degenerative osteoarthritis associated with osteopetrosis. *Clin Orthop*, 1977, 127, 148.
6. CASDEN AM, JAFFE FF, KASTENBAUM DM, BONAR SF : Osteoarthritis associated with osteopetrosis treated by total knee arthroplasty. *Clin. Orthop*, 1989, 247, 202.
7. FREEMAN MA, BRADLEY GW : ICLH surface replacement of the hip. An analysis of the first ten years. *J Bone Joint Surg (Br)*, 1983, 65, 405.
8. GRENFIELD GB : Radiology of Bone Disease. 4th ed. Philadelphia. *Lippincott Co*, 1986, 395.
9. HOWIE DW, CAMPBELL D, MCGEE M, CORNISH BL : Wagner resurfacing arthroplasty. *J Bone Joint Surg (Am)*, 1990, 72, 708.
10. JANECKI CJ, NELSON CL : Osteoarthritis associated with osteopetrosis treated by total replacement arthroplasty. *Cleve Clin Q*, 1971, 38, 169.
11. KING RE, LOVEJOY JF : Familial osteopetrosis with coxa vara. *J Bone Joint Surg (Am)*, 1973, 55, 381.
12. RITTER MA, GIOE TJ : Conventional versus resurfacing total hip arthroplasty. A long-term prospective study of concomitant bilateral implantation of prosthesis. *J Bone Joint Surg (Am)*, 1986, 68, 216.
13. ROBINCHON J, WILEY JJ, GERMAIN JP : Osteopetrosis. *Can J Surg*, 1968, 11, 424.